

“Use of the Tulip™ Microcannula Closed Syringe System For Safe and Effective Lipoaspiration and Autologous Fat Grafting”

Robert W. Alexander, MD, DMD, FICS

University of Washington, School of Medicine & Dentistry Seattle, Washington

rwamd@cybernet1.com

ABSTRACT

Objectives: Provide background for use of acquiring autologous adipose tissue as a tissue graft and source of adult progenitor cells for use in Cosmetic-Plastic Surgery. Discuss the background and mechanisms of action of closed syringe vacuum lipoaspiration, with emphasis of accessing adipose tissues for use in aesthetic, structural reconstruction, and regenerative applications. Explain a proven protocol for acquiring high quality autologous fat grafts with use of Tulip™ disposable, microcannula systems.

Design: Explain the components and advantage of use of the patented super luer-lock and microcannulas system for use with the Tulip™ Medical closed syringe system. A sequential explanation and equipment selection for minimally traumatic lipoaspiration in small volumes is presented, including use of blunt injection cannulas to reduce risk of embolism.

Results: Thousands of autologous fat grafts (AFG) have proven safe and efficacious for lipoaspiration techniques for large and small structural fat grafting procedures. The importance and advantages of gentle harvesting the adipose tissue complex (ATC) has become very clear in the past 5 years.

The closed syringe system offers a minimally invasive, gentle system to mobilize subdermal fat tissues in a suspension form. Resulting total nuclear counts that suggest the ability to achieve higher yields than use of always on, constant mechanical pump applied vacuum systems.

Conclusions: Use of Tulip™ closed syringe lipoaspiration system featuring disposable microcannulas offers a safe and effective means of harvesting small volumes of non-manipulated adipose tissues and its accompanying progenitor cells within the SVF. Tulip™ syringe and microcannulas offer a sterile, disposable compact closed system, and practical protocol for acquiring high quality autologous fat grafts

KEYWORDS: Autologous fat grafting; closed syringe Lipoaspiration; Adipose-derived adult mesenchymal stem cell; adipose-derived progenitor cells; adipose-derived stem cells; adipose-derived stromal cells; bioscaffolds; lipoaspiration; lipo harvest; liposuction; stromal vascular fraction; SVF.

Introduction & Background

For many years, cosmetic-plastic surgeons have recognized the value of low pressure lipoaspiration for successful transplantation of adipose tissue for structural augmentation. In the introductory years (1980-1990) of liposuction techniques, autologous fat grafting (AFG) was considered unpredictable. Once bioengineers discovered the actual mechanisms by which lipoaspiration worked, the closed syringe system for gentle harvesting and transplantation was developed and patented. Early belief that effective lipoaspiration was directly related to force of vacuum was replaced by understanding, that, introduction of fluid into the fat layers permitted the adipocyte cells and stromal elements to enter into a suspension state. This suspension was then easily extracted through use of closed syringes, and provided adipose tissues with reduced cellular damage via a closed syringe system, and led to improved and more predictable grafting results.¹

As the importance of tumescent fluid distribution was appreciated, more value was placed in extensive pre-tunneling (moving cannula without applying vacuum). This better distributed local solution and enhanced the ability to mobilize the adipose tissues into a suspension state, yielded more successful structural grafting, and predictable autologous fat grafts (AFG) results.

In the early 2000s, appreciation of the potentials of adipose tissue and its related stromal elements, led to examination of the adipose-derived adult stem-stromal cell content within the adipose tissue complex (ATC).^{2,3} Evidence has shown the importance of these associated nucleated cells as integral contributors to the tissue maintenance and healing processes.⁴ Studies of adipocyte homeostatic replenishment (following normal senescence and cellular death) show that these attached cells within the adipose complex were activated to create adipocytes and thereby maintain adipose tissue integrity over time.⁵ Since there is safe, plentiful, and easily accessible graft tissue provided by gentle lipoaspiration, utilization of the entire adipose tissue complex as a central focus in optimizing effectiveness of autologous fat grafting in cosmetic-plastic surgery and clinical regenerative medicine has evolved.⁶⁻⁸

Pre-clinical and clinical applications have been reported in many scientific studies in the biological, bioengineering, and clinical medical literature.¹¹ Cosmetic-plastic surgeons initially focused on understanding the mechanisms to achieve safe and effective AFG. It was believed that intact cellular (mature adipocytes) transplantation was the most important goal. However, it is now understood that mature adult adipocytes transplanted may be the least important feature producing long-term success, even in structural fat augmentation graft applications. Current beliefs are that success in long-term AFG is actually due to activation of associated cells, followed by proliferation of those to differentiate into the adipocytes for volume replacement.⁹

For example, placement of lipoaspirants into existing adipose tissue favors proliferation and differentiation into adipose cell phenotypes. As understanding of the maintenance (homeostatic) and replenishment of adipose cell cycles in Vivo increases, extensive research is being devoted to the study of microenvironment (niche), cell-to-cell/cell-to-matrix factors, and autocrine/paracrine signaling system functions.

Rapidly accumulating clinical data on the safety and efficacy of autologous fat grafting provides clear evidence that fat tissue grafts possess extensive potentials in wound healing, well beyond the structural augmentation in cosmetic-plastic surgical uses.

Understanding these mechanisms resulted in important application potentials for aesthetic, reconstructive, and regenerative medicine. Reporting of pre-clinical, early clinical, and controlled studies in animal and human models, shows worldwide recognition of the potentials uses of these cells in diverse areas of medicine and surgery.

Autologous Fat Grafts For Use In Aesthetic-Reconstructive Surgery

Research and clinical applications have led to appreciation of the existence of a large heterogeneous nucleated cell population and extensive native bioactive scaffolding that is an integral component of adipose tissues.

With advanced understanding of the processes of homeostatic adipose replacement, many reasons why carefully harvested autologous fat grafting for structural augmentation is effective have become much more predictable and understood than in year's past.

The patented Tulip™ closed syringe system with its array of microcannulas (small volumes-<100 cc) and standard volume reduction cannulas (for >100 cc liporeduction and contouring) is a recognized and proven lipoaspiration

system. Explanation and detailed discussion of a repeatable, effective, and safe protocol for adipose tissue complex harvest for cosmetic-plastic surgeons will be provided in this paper.¹⁰

Materials & Methods

Selection of Lipoaspiration Sites

The lower abdomen and flank areas of both males and females are considered ideal sites due to distribution of human adipose tissues and relatively large deposits. Choice of aspiration sites in the medial and lateral thigh/buttocks areas are sometimes favored for lipoaspiration and adipose graft harvesting in female patients due to genetic distribution within the gynoid body type. In very low percentage body fat patients needing autologous grafts, use of a high definition ultrasound probe is helpful to determine the thickness and depth of adipose deposits which can be acquired.

Preparation of Lipoaspiration Sites (Donor & Recipient)

The patients may be placed in either supine or lateral decubitus position to facilitate the preparation and complete sterile isolation of the proposed donor area(s). It is considered important to follow a standard sterile protocol for both the harvesting and placement sites. Routine operative site asepsis should be maintained in all cases, with patients marked in an upright or standing position to effectively mark the area of available or unwanted adipose tissue deposits.

Microcannula Instrumentation

The patented Tulip™ Medical closed syringe system for lipoaspiration features very smooth cannulas and a “super” luer-lock connection for use with standard luer-lock syringes. (Figure 1.) This hub connection is a very important component of the closed syringe and microcannula system, in that it provides an excellent seal for maintaining even vacuum forces desirable during lipoaspiration. Since the super-luer lock connection seals at both the internal luer connection, but also seals at the outer ring of the standard luer connection. It thereby provides a very stable, rigid base when using very small cannulas and their associated flexibility within the tissues. Internal female luer-type connectors on some microcannula systems on the market become less efficient when cannulas are redirected, placing a torque on the junction of cannula-syringe barrel, and allowing air leakage into the closed system (particularly in the

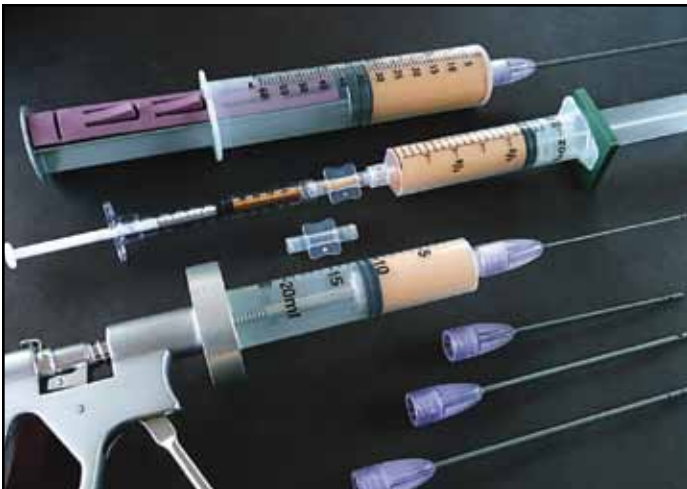

Figure 1. Tulip GEMS Disposable Microcannula Set

longer cannula selections). This does not usually prevent aspiration capabilities, but it does decrease the efficiency and may introduce cavitation to the harvest tissues.

Two standard options for microcannula selection offered within the Tulip™ system are:

1. Cell-Friendly Microcannula option (autoclavable) (Figure 2.):

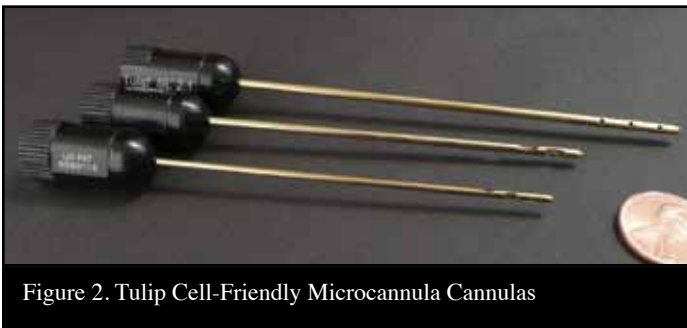

Figure 2. Tulip Cell-Friendly Microcannula Cannulas

These cannulas are internally polished by microabrasive extrusion process to maximize internal smoothness and reduce adipose tissue damage to the adipocytes, precursor cells, and their accompanying matrix. External cannula anodizing processes provide a smoother surface for ease of passage within the subdermal adipose plane. This is a popular design utilized by plastic-cosmetic surgeons for liporeduction as well as harvesting of autologous fat grafts for structural augmentation procedures and larger bore cannula sets. In cannulas of less than 3.0 mm, it is important to thoroughly flush with water-prep soap mix, followed by ultrasonic cleaning, and thoroughly re-flushing with water prior to steam or gas sterilization. It is VERY important to avoid use of brushes for internal cannula cleaning, as they will damage the highly polished interiors.

2. Sterile, Coated Disposable Microcannula Option (Figure 3.):

Use of disposable microcannulas in small diameters of less than 3.0 mm (range 0.9-2.4 mm OD) presents a significant challenge to insure proper and effective cleaning- sterilization cycles mandatory with use of the reusable option, making a disposable option attractive, particularly in the smaller diameter cannula group. These are packaged and labeled in a sterile wrap, and can be opened directly onto the sterile field or back table. Featuring the super luer-lock base, these stainless steel cannulas are totally coated internally and externally with a hydrophilic material which provides an extremely smooth coating, permitting easy passage through adipose tissues with minimal resistance and trauma. Initially hydrogel coatings were applied on both internal and external surfaces, but now have been replaced by more efficient and effective coating materials, featuring more than 20 times more lubriciousness than previous coating materials. It is believed that the least cellular and tissue trauma created, the better the quality of the adipose grafts.

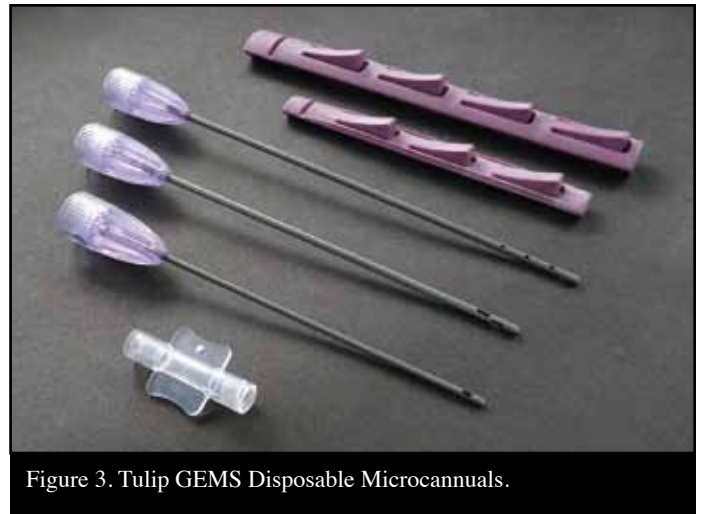

Figure 3. Tulip GEMS Disposable Microcannulas.

With increased recognition of difficulties in effectively cleaning the non-disposable microcannulas (<3.0 mm), most surgeons are choosing use of completely disposable infiltration, harvesting and injection cannulas.

Selection of Microcannula Length and Diameters

For small volume applications (<100 cc), it is recommended to use a small, multiport Infiltrator Cannula for even and thorough distribution of local anesthesia throughout the adipose donor layer. Openings near the tip are multiple and oriented such that 360 degree distribution of local while moving through the subdermal fat layers. It is common for




Figure 4a. Tulip Cell-Friendly Microcannula Multiport Infiltrator (Top) Tulip Microcannula Offset Harvester (Bottom)
 Figure 4b. Tulip GEMS (Infiltrator, Harvester, and Injection Cannula)

practitioners to use this infiltration cannula in diameters of 2.1 mm OD and a length of 10-20 cm. (Figures 4a & 4b.)

Harvesting Cannulas are designed to actually acquire the adipose tissue grafts from the subdermal fat plane, following the same pattern and location of local anesthesia distribution.

The openings on the harvesting cannulas are typically in-line or offset (meaning in a non-linear pattern of openings near the tip of the cannula). These vary in diameters of 1.67 mm to 2.4 mm (OD), and a length of 10-20 cm. Selection of a slightly shorter harvesting cannula compared to length of infiltrator, makes it somewhat easier to remain within the local anesthesia distribution areas for awake patients.

Tulip™ Syringe Locks come in two options, an “external” and “internal” form. The external locks are specifically designed for use on BD or Monoject 10/12 and 20 cc luer-lock syringes and 60 cc Toomey tip syringes to hold the syringe plunger in a fully drawn position during the application of vacuum. (Figure 5.) Before application of vacuum by pulling the syringe plunger to the desired level, it is essential to draw sterile saline fluid into the cannula to completely displace all air within the system. When pulled and twisted into the locked position, the edge of the lock engages the side of the plunger permitting the physician to apply even

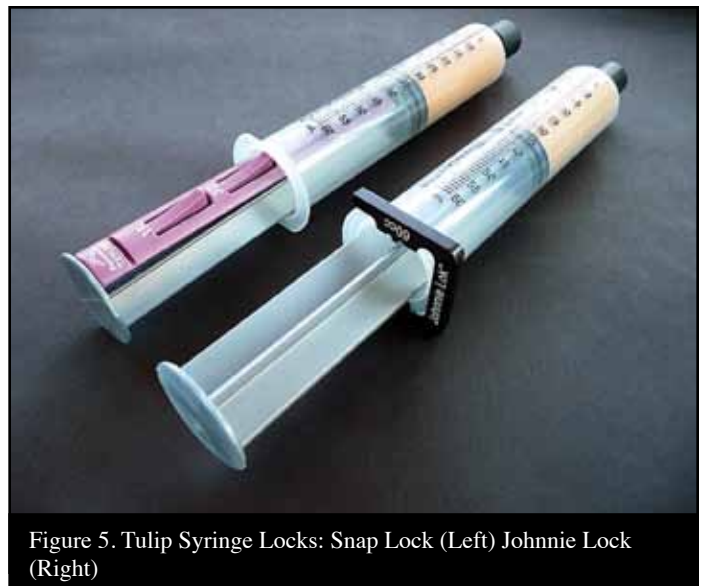


Figure 5. Tulip Syringe Locks: Snap Lock (Left) Johnnie Lock (Right)

and gentle vacuum pressures while moving the cannula through the tumesced adipose layer. The “internal” type lock is called a Snap Lock, is available and universally fits varied manufacturers of syringes and sizes.

Anaerobic Transfers (luer-to-luer) are available to facilitate anaerobic loading of treatment syringes prior to grafting procedures, and for optional use of additives to the grafts (such as combining platelet concentrates (HD PRP) to the adipose grafts) into the same syringe. They are also useful for transferring the graft treatment mix into syringe sizes of physician’s preference for injection and avoiding undesirable exposure of the harvested graft to air. (Figure 6.) It is considered important to avoid excessive air exposure to grafts due to the potential for contamination by airborne particles or pathogens. Techniques described as helpful in free lipid removal (such as Telfa™ rolling) are vulnerable to such contamination.

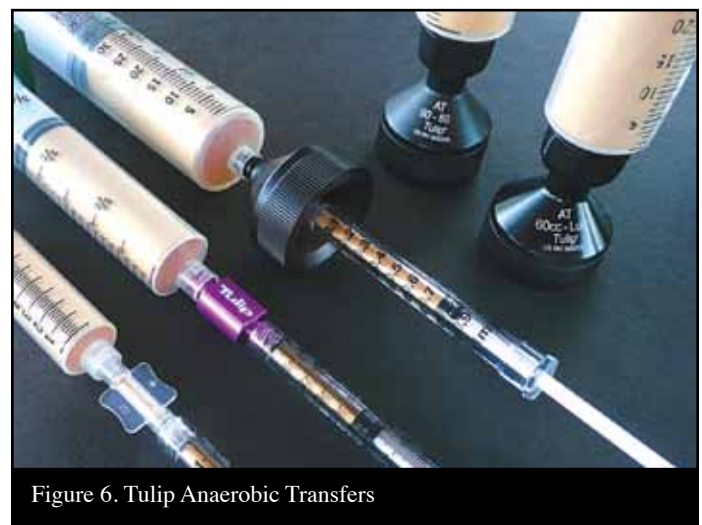

Figure 6. Tulip Anaerobic Transfers

A controlled aliquot Injector Gun is available for placement of controlled 0.5 cc aliquots of graft into the prepared tunnels and locations. When additives are added to the adipose tissue graft, the density of the injection material may be increased. This may result in the physician requiring more force to inject into the tissue site, or, encountering sudden and uneven distribution of desired small aliquots of graft with prepared tunnels associated with adipose matrix density within the graft itself. Single trigger pull provides exact volumes of solution to be placed with less pressure required by the provider. (Figure 7.)

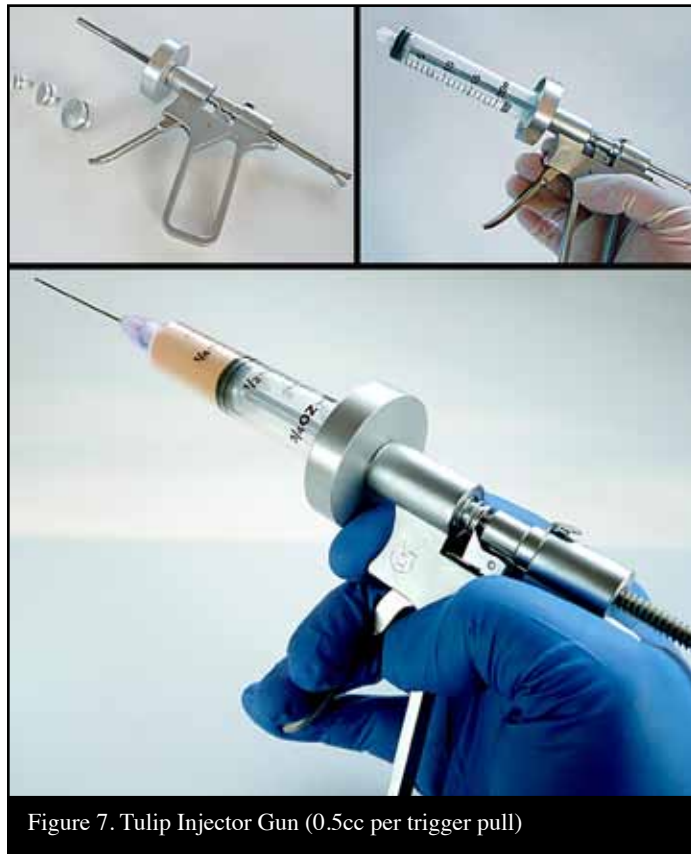

Figure 7. Tulip Injector Gun (0.5cc per trigger pull)

Sequential Technique For Performing Microcannula Lipoaspiration

It is recommended that the area of donor and recipient sites be outlined, with patient in upright position using skin marking pencil. This will become the area prepped-draped to expose the thickest deposit of palpable fat tissues and serve as a distribution pattern for local anesthetic infiltration. (Diagram 1.)

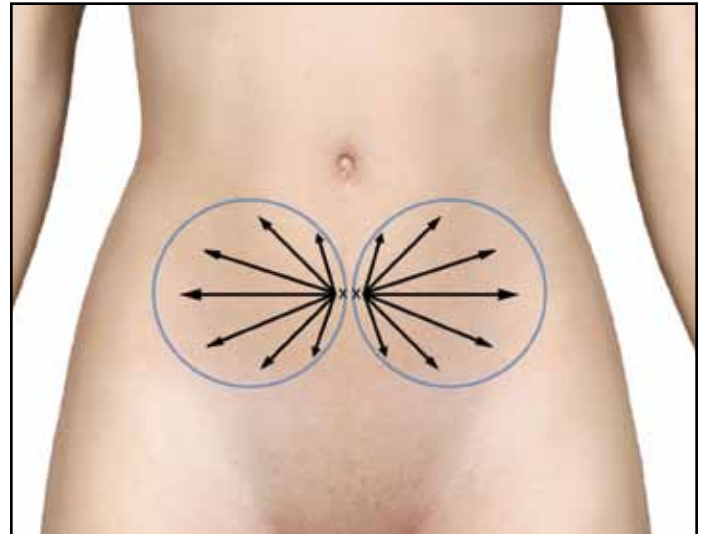


Diagram 1. Sample Marking For Small Volume Harvest Abdomen.

After marking, preparation, and sterile isolation of the donor area, an 18-20 g needle side edge positioned vertically, and which is utilized to create a small slit-like opening, extending through the epidermis and dermis, into the subdermal fat plane of the donor site. It is important to avoid too large an opening, as the closed syringe system vacuum depends on maintaining a tight side wall opening to insure even vacuum application. Use of stab incisions with scalpel blades of #15 or #11 sizes tend to create a larger than necessary or desired openings. This opening is made larger by selectively cutting the dermal layer (under the skin surface) with edge of the needle bevel. This allows the introduction of the multiport infiltration cannula through the skin and the subdermal fascia (and should perforate and remain below Scarpa's Fascia in the abdomen). In large cannula sizes, use of a tapered stainless sharp trocar (3 mm) is utilized to permit snug fit of the aspiration cannulas into the desired space. (Diagram 2)

Following entry, the multiport infiltrator cannula is passed in a horizontal fashion within subcutaneous donor fat deposit, above the muscular layer, in a "spokes-of-a-wheel" pattern. Pinching the skin-fat tissues may help in passing the cannula. During movement of the infiltrating cannula, very slow injection of the tumescent local anesthesia fluid is provided on both the entry and withdrawal strokes, evenly,

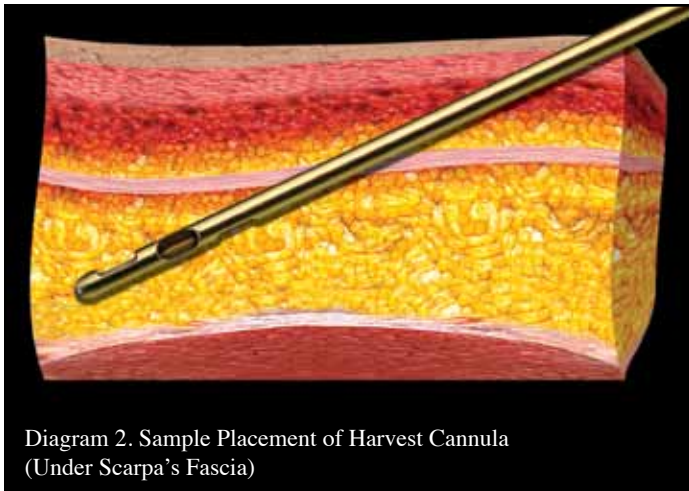


Diagram 2. Sample Placement of Harvest Cannula (Under Scarpa's Fascia)

and in layers. The importance of avoiding “pooling” of local is that evenly distributing liquids improve the efficiency of harvest due to the need to provide a suspensory fluid carrier for the adipose graft tissues, as well as providing excellent patient comfort.

In typical small volume grafting cases, use of local or tumescent solution range from 20-30 cc during the infiltration process, using a general guideline of at least a 1:1 ratio to anticipated fat harvest volume. Example, if the plan is to aspirate 50 cc of adipose tissues, then use of 50 cc, or greater, of fluid volume is distributed with the adipose layer to provide the fluid carrier for extraction of the grafts. A common example of the component of tumescent solution is to select add the contents 50 cc multi-dose vial of local anesthetic (e.g. 0.5 to 1.0% Xylocaine with, or without, epinephrine (1:100,000) to 1 liter of sterile saline or balanced salt solution to provide sufficient tumescent fluid for lipoaspiration.

Upon completion of even distribution of tumescent fluid within the proposed donor area, it is recommended that re-passage of the infiltrating cannula throughout the donor area (termed “pre-tunneling”) multiple times is important and very helpful to attain an even and high quality graft. This more thoroughly distributes local anesthetic fluid for patient comfort, and it also provides the needed “carrier fluid” to suspend the adipose tissues prior to harvesting with low pressure and minimal bleeding.**

**Note: This is a very important step which will improve comfort during harvest, plus make extraction more efficient and result in markedly less volume of the unwanted infranatant fluid layer.

In small volume transfers, most practitioners select a 20 cc luer syringe attached to the harvesting microcannula with a mounted locking device. A very small volume (1-2 cc) of sterile 0.9% saline is drawn into the cannula to displace air from the system prior to insertion into the harvest (donor

site). This is termed “charging” the syringe device, and is necessary to eliminate all air within the cannula and syringe, thereby avoiding cavitation produced when using mechanical pump suction devices (wall suction, de-tuned lipoaspiration machines, etc.).

Once the harvesting cannula is inserted into the locally tumesced adipose layer, the syringe plunger is drawn to partial or full extension depending on desired vacuum pressure, and twisted to provide a “lock” if using an external type, or to a ledge which snaps to hold the plunger in one of three positions. After application of vacuum, the physician is free to move the harvesting cannula in a forward and back series of passages. It is important that these passages are within the same plane and same pattern as used during the placement of tumescent solution. Adipose return, at first, will be somewhat slower, as the graft tissue must be in suspension to be able to be easily extracted. Continuing these movements with vacuum applied will yield adipose tissues with minimal bleeding in most patients.

NOTE: In the event of vacuum pressure loss during the harvesting process, it is sometimes necessary to completely remove the harvesting cannula from the donor site, carefully express all air from within the cannula. When this is completed, re-insertion of the cannula is performed, and activation of vacuum restarted upon pull and locking of the syringe plunger.

The yellow adipose grafts will quickly gravity separate from the underlying (infranatant fluid), resulting in the graft floating on top of the small fluid volume within the syringe system. Test tube/syringe stands or decanting stands are available to facilitate this initial gravity separation. (Figure 8 a,b)




Figure 8a. Tulip Decant Stand (Luer)
Figure 8b. Tulip Decant Rack Option

During the displacement of air, it is recommended that 4x4 sterile gauze be held over the harvesting tip openings to avoid spraying contents. Occasionally, in cases where there is a larger volume of infranatant fluid (the layer immediately below the fat tissues), simply express the liquid portion, and re-insert the harvesting cannula into the harvest site, lock the plunger, and gather more graft tissue.

One common cause of increased infranatant volume in the decanted syringe is inadequate distribution of local fluid, creating a “pooling” effect, which reduces efficiency of adipose harvest. It is for this reason that extensive pre-tunneling is highly recommended prior to application of any vacuum to the tissues. Upon completion of aspiration of the desired graft volume, the harvester cannula is removed, and the syringe end capped and placed in a vertical position in a standard test tube rack or directly onto a decanting stand to allow gravity to separate the layers within the syringe. This usually requires decantation for approximately 2-3 minutes. Following this period, practitioners expel the unwanted liquid layer on which the fat graft floats into sterile containers for disposal.

If additional graft is needed, it is possible to expel the infranatant completely, and re-insert the harvester into the donor site to acquire more graft prior to decanting and loading the graft into the treatment syringes of choice. When the desired volume is obtained, lipoaspiration is completed, and the small opening is covered with a triple antibiotic ointment and a Coverlet bandage (adhesive on all sides).

Ideally, the more thorough removal of infranatant fluids from the graft yields a more dense cellular graft. In addition, the free lipid layer (clear yellow liquid above the harvested graft) should be avoided when transplanting the autologous graft. This layer is irritating, and prolongs the healing of the graft tissues as it must be removed during the process by macrophages, etc. over time. Many practitioners recommend use of centrifugation to accomplish more ideal separation than use of gravity decanting alone. In addition, some perform 1-2 rinses with sterile saline to help reduce any residual local anesthetic solution and red blood cells in specimens with slightly greater blood within the harvested grafts.¹¹

After decantation and/or centrifugation steps, the graft preparation is ready for placement into treatment syringes of physician’s choice. It is important to use the clear anaerobic transfers (luer-to-luer connectors) to load the individual application syringes from the prepared, compressed graft. It is believed to be advantageous to avoid external air exposure and potential for contamination. Within the transfer options, use of luer-to-luer emulsification capabilities are available, which preserve the anaerobic, closed status

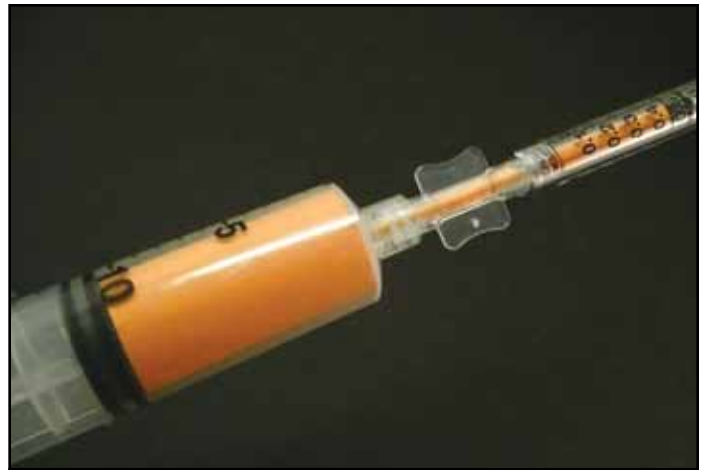

Figure 9. Tulip GEMS Anaerobic Transfer (Shown Loading Treatment Syringe).

of the grafts and permit the option of emulsification if so desired. (Figure 9)

Selected treatment syringes are then mounted with the desired injection cannulas using coated, single port cannulas. Use of blunt, coated cannulas are recommended, particularly within the facial recipient areas to lower the risk of embolism caused by inadvertent injection of the adipose graft intravascularly. The injection cannulas are available in a variety of lengths and diameters (ranging from 0.9 mm to 1.47 mm OD), to accommodate the surgeon’s preference and specific areas to be grafted. Some elect to inject with sharp needles ranging in size from 18 g to 25 g. (Figure 10)

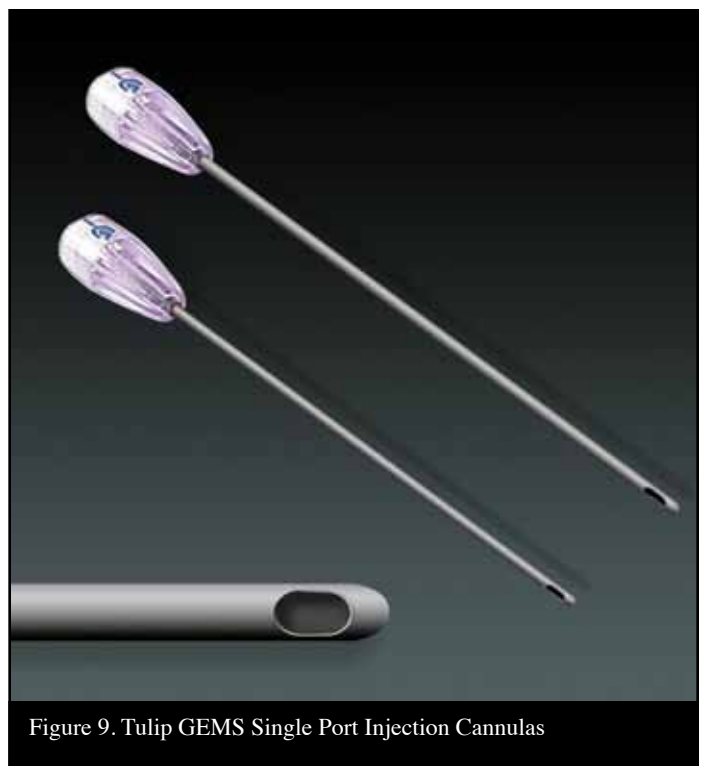


Figure 9. Tulip GEMS Single Port Injection Cannulas

The typical graft recipient bed is prepared and developed by pre-tunneling to create a “potential” space, which is subsequently filled in small aliquots and in layers as the injection cannula is being withdrawn.

It is recommended that the donor sites be dressed in a proper fashion. Use of small, sterile gauze dressing placed over the actual opening created to place the tumescent fluids into the subdermal tissues will absorb any excess residual fluids displaced by adipose during the harvesting process. Further, placement of a closed cell, medical grade foam (TenderFoam™) over the entire surface above the harvested areas, with use of external compression, will eliminate or minimize post-harvest bruising of the donor area. Compression of the gauze and TenderFoam for 24-48 hours is typically effective. (Figure 11.)




Figure 11a. TenderFoam Patch (To Limit or Prevent Bruising)
Figure 11b. TenderFoam Sheet (Overlay Liposuction Sites) Prior to Compressions

Discussion

When the mechanisms involved in liposuction technologies were recognized in the mid-late 1980s, the ability to provide small and large volume liposuction via the closed syringe system was proven safe and more predictably effective. Due to even, low vacuum pressure application offered by syringe use, enhanced abilities to provide superficial plane lipoplasty capability was proven. This included removal of significantly larger volumes in a single session, and reduction of deposits within the superficial plane. This ability was credited to aid in skin redraping and improved contouring results. Besides volume implications, the syringe launched the beginning of more consistent and predictable autologous fat grafting procedures, with safety, efficacy, and reproducible results within aesthetic surgical applications. Structural fat grafting, utilizing the exact techniques herein described has been completed many thousands of times by many cosmetic-plastic surgeons. Science has now provided important information to help explain the homeostatic and transplant acceptance mechanisms accomplished by autologous fat. As appreciation of the biocellular nature of the adipose tissue complex increases, the importance and value of the SVF has gained major attention. It is becoming mainstream knowledge that the actual transplanted mature adipocytes are gradually lost, while serving an important role in their own replacement from attached near-terminally differentiated cells. For several years, leading practitioners sought to achieve pure, adipocyte grafts, without regard to the SVF components and the effects of the local microenvironment available with the recipient fat tissues. The importance of signaling and growth factor secretion associated with certain paracrine effects, have changed the treatment paradigm of small volume structural grafting. It is now clear that the entire adipose tissue complex provided by lipoaspiration play an important integral role in achieving structural augmentation, as components participate in stimulation of the recipient site to accept the grafted cells and heal the sites. Final differentiation into metabolically active adipocytes is felt to contribute to lipid metabolism and volume storage needed to accomplish structural augmentation using autologous fat grafts. . Both the AFG and additive effects are further enhanced in the surgically damaged recipient tissues through complex “signaling” mechanisms of autocrine and paracrine pathways in Vivo.

Conclusion

This paper presents a simple and effective method of lipoaspiration to harvest adipocytes and their accompanying progenitor and stromal elements using the Tulip™ closed syringe system. Effective for lipoaspiration of small and large volumes, the use of closed syringe system and its accessories offers a full range of options to fulfill all needs for autologous fat grafting. The safety and efficacy of using the patented Tulip™ closed syringe system has evolved to use of coated, disposable microcannula system specifically designed for use in structural autologous fat harvest and transfer. It currently serves as the most complete and effective gold standard for all closed syringe systems.

Disclaimer: Author has no conflicts of interest or financial relationship with Tulip Medical™, Johnson and Johnson (J & J) Telfa™, or T & N Industries (TenderFoam™).

References

1. Alexander, R.W. Liposculpture in the superficial plane: Closed syringe system for improvements in fat removal and free fat transfer. *Am J Cosm Surg*. 1992; 11:127-134.
2. Zuk P, et al. Multilineage cells from human adipose tissue: implications for cell-based therapies. *Tissue Eng*. 2001; 7(2):211-238.
3. Zuk P, et al. Human adipose tissue is a source of multipotent stem cells. *Molec Biol Cell*. 2002; 13: 4279-4295.
4. Yoshimura, K., et al. Characterization of freshly isolated and cultured cells derived from the fatty and fluid portions of liposuction aspirants. *J Cell Physiol* 2006; 208(1): 64-76.
5. Alderman, D, Alexander, R.W., et al. Advances in Regenerative Medicine: High-Density Platelet-Rich Plasma and Stem Cell Prolotherapy. *J. Prolo*. 2011; 10(Oct): 49-90.
6. Doi, K, et al. Cellular origin in adipose tissue remodeling after transplantation. Presentation IFATS 2011 #62, Miami.
7. Alexander, R.W., et al, Platelet-rich plasma (PRP) utilized to promote greater graft volume retention in autologous fat grafting. 2006 *Am J Cosm Surgery* 23(4): 627-631.
8. Gimble, J. et al. Adipose-derived stem cells for regenerative medicine. 2007, *Circ Res* 100(9): 1249-1260.
9. Alexander, R.W., Understanding Adipose-Derived Stromal Vascular Fraction (SVF) Cell Biology On The Basis Of Cellular, Chemical, Structural and Paracrine Components. *J of Prolo (JOP)* 2012; 4(1): 855-869.
10. Alexander, R.W. Autologous fat grafts as mesenchymal stroma/stem cell source for use in Prolotherapy: A simple technique to acquire lipoaspirants. *J Prolo* 2011; 3(3): 639-647.
11. Alexander, R.W.. Autologous fat grafting: a study of residual intracellular adipocyte lidocaine after serial rinsing with normal saline solution. In: *Autologous Fat Grafting*, ed. Shiffman, Springer. Berlin, 2010: 58:445-450.